



Univ.-Klinik für Augenheilkunde und Optometrie  
Paracelsus Medizinische Privatuniversität  
Universitätsklinikum, Landeskrankenhaus  
Müllner Hauptstr. 48  
A-5020 Salzburg □

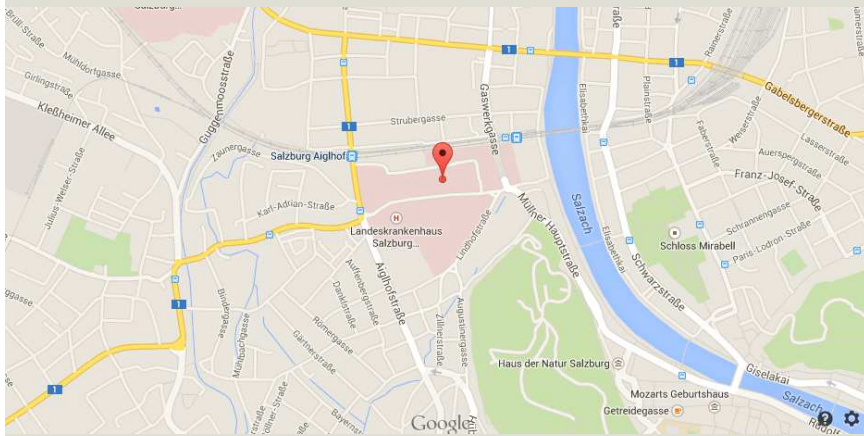
#### Arrival

##### From main railway station by bus:

- Stop LKH/Mülln: Line 1 or 2, change at the stop Gaswerkergasse in Line 7 or 8
- Stop LKH/Aighhof: direct with the Line 2

##### By car:

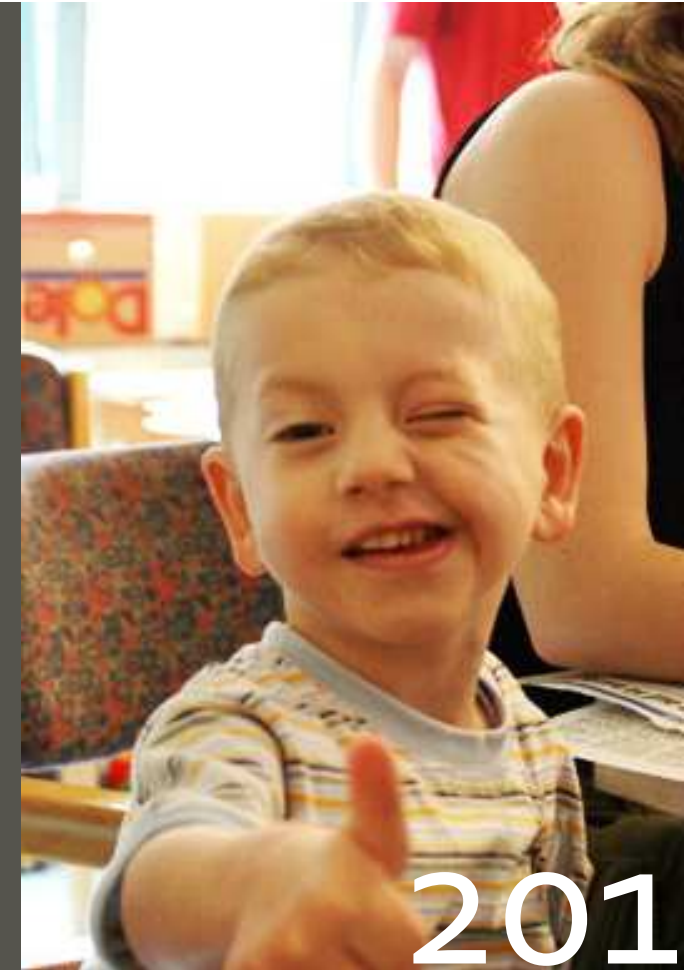Motorway exit "Salzburg Mitte" direction of centre - Münchner Bundesstrasse - Lieferinger Hauptstrasse - Ignaz-Harrer-Strasse - turn right into Gaswerkergasse - after the underpass turn right - entrance Mülln.



**Organization:** Anja Karl, Kinderklinik Traunstein, Cuno-Niggel-str.3, 83278 Traunstein

phone: +49-861-705-33260

mail: kindertagesklinik.ts@kliniken-sob.de



# 2015

Cystinose-Selbsthilfe e.V. – Patient Organization  
Cystinosis foundation Germany

**Cystinosis:  
Ophthalmological symposium for patients  
and physicians**

08<sup>th</sup> – 10<sup>th</sup> October 2015

Eye Clinic of the PMU Salzburg

# Program

## Thursday 08 October 2015

- 09:00 am - 12:00 pm Ophthalmological characteristics and therapeutic options for cystinosis patients
- 01:30 pm - 04:30 pm Presentation of cases
- From 04:30 pm Get together

## Friday 09 October 2015

- 08:30 am - 12:00 pm Presentation of cases
- 01:30 pm - 03:30 pm Presentation of cases
- 04:00 pm - 05:30 pm Wrap-up
- From 06:30 pm Dinner together

## Saturday 10 October 2015

- 08:30 am - 12:00 pm Preparation of international guidelines

## Contributing people

### Prof. Jennifer Simpson, Director of the course

Clinical Professor, Gavin Eye Institute  
University of California, Irvine

### Dr. med. Rousan Aghayan-Ugurluoglu

Medical specialist for ophthalmology, Salzburg

### Prim. Univ.-Prof. Dr. G. Grabner

Director, University Eye Clinic  
Paracelsus Medical University, Salzburg

## Organizers and sponsors

Cystinose-Selbsthilfe e.V. – Patient Organization  
Cystinosis foundation Germany

# Objectives

## Cystinosis

Cystinosis is a very rare metabolic disease. Apart from the kidney, the eye is the major organ which is affected. In addition to the systemic therapy with Cysteamine a local application is essential.

Characteristic deposits of cysteine crystals in the cornea can be detected with a slit lamp examination at a very early stage. The edge-focused accumulation is typical, whereby only the front layer in the center of the cornea is affected. This distribution pattern is so characteristic that this examination should be sufficient for the exclusive diagnosis.

## Objectives of the symposium

- Establishment of an ophthalmological standard of treatment
- Type of application
- Therapeutic options
- Preparation of international guidelines

